



ELSEVIER



9

---

## Office hysteroscopy and adenomyosis

Carlos Roger Molinas\* MD, PhD

*Centre for Gynaecological Endoscopy (Cendogyn), Centro Médico La Costa, Asunción, Paraguay*

Rudi Campo MD

*Leuven Institute for Fertility and Embryology (LIFE), Leuven, Belgium*

---

Adenomyosis, the heterotopic presence of endometrial glands and stroma within the myometrium, has traditionally been diagnosed by the pathologist in hysterectomy specimens. However, the recent development of high-quality non-invasive techniques such as transvaginal sonography (TVS), magnetic resonance imaging (MRI) and hysteroscopy has renewed interest in diagnosing adenomyosis in the office prior to any treatment. Hysteroscopy offers the advantage of direct visualization of the uterine cavity, and since nowadays it is performed in the office, it can be offered as a first-line diagnostic tool for evaluation of uterine abnormalities in patients with abnormal uterine bleeding and/or infertility. The available data clearly indicate that high-quality mini-hysteroscopes, saline as a distension medium, and atraumatic insertion technique are essential for the success of office hysteroscopy. The procedure is indicated in any situation in which an intrauterine anomaly is suspected; it is immediately preceded by a physical exam and a TVS to evaluate uterine characteristics, and it is followed by a second TVS to take advantage of the intracavitary fluid for a contrast image of the uterus. Although diagnostic hysteroscopy does not provide pathognomonic signs for adenomyosis, some evidence suggests that irregular endometrium with endometrial defects, altered vascularization, and cystic haemorrhagic lesion are possibly associated with the entity. In addition to the direct visualization of the uterine cavity, the hysteroscopic approach offers the possibility of obtaining endometrial/myometrial biopsies under visual control. Since they can be performed in the office, the combination of TVS, fluid hysteroscopy and contrast sonography is therefore a powerful screening tool for detecting endometrial and myometrial abnormalities in association with adenomyosis.

**Key words:** adenomyosis; hysteroscopy; diagnosis; ambulatory.

---

Adenomyosis is a common benign gynaecological disorder characterized by the heterotopic presence of endometrial glands and stroma within the myometrium, surrounded by smooth muscle proliferation. The degree of myometrial invasion is

---

\* Corresponding author. Tel.: +595 21 214810; Fax: +595 21 214035.

E-mail address: [roger.molinas@lifeleuven.be](mailto:roger.molinas@lifeleuven.be) (C.R. Molinas).

variable and can involve the whole uterine wall up to the serosa. Because the junction between endometrium and myometrium (endometrial–myometrial interface, EMI) in normal uteri is often irregular, the exact criteria for the histopathological diagnosis of adenomyosis are controversial. Indeed, some pathologists make the diagnosis of adenomyosis when any penetration of the myometrium by tongues of endometrium is found, whereas others demand either the presence of hypertrophic myometrium around the foci of endometrium, or a specific depth of penetration, or both. For instance, Uduwela et al require an endometrial extension  $>2.5$  mm below the EMI for making the diagnosis,<sup>1</sup> whereas Bird et al describe the so-called adenomyosis sub-basalis when the depth of penetration beneath the basal endometrium is  $<2.0$  mm.<sup>2</sup> The prevalence of the condition therefore varies depending on the diagnostic criteria chosen (from 10% to 35% of hysterectomy specimens), being more frequent in multiparous women in their fourth or fifth decade of life.

The myometrium often presents a degree of hyperplasia and a trabeculated cut surface, resulting in the typical increase in uterine size, the posterior wall being more frequently affected than the anterior wall. There are two forms of adenomyosis: diffuse and focal. While diffuse adenomyosis determines varying degrees of diffuse uterine enlargement, focal adenomyosis (also known as adenomyoma) presents as a localized mass difficult to differentiate from leiomyoma.

Typically a soft and enlarged uterus is found during the physical exam, and the symptoms include menorrhagia, metrorrhagia, dysmenorrhoea, dyspareunia and/or dyschezia, frequently mimicking those symptoms present in leiomyomas, endometriosis, or dysfunctional uterine bleeding. Infertility is a less common complaint since adenomyosis is more often diagnosed in women in their 30s or 40s. However, since nowadays many women delay their first pregnancy until that age, adenomyosis is increasingly being found during infertility diagnostic work-up.

Both the clinical features and gross pathological findings of adenomyosis obviously depend on the microscopic diagnostic criteria chosen. If the disease is diagnosed with less extensive criteria, the prevalence will appear higher and will more frequently be asymptomatic.

Adenomyosis has traditionally been diagnosed by the pathologist in hysterectomy specimens or with invasive techniques such as percutaneous or laparoscopic uterine biopsies.<sup>3</sup> However, the recent development of high-quality non-invasive techniques – e.g. transvaginal sonography (TVS) and magnetic resonance imaging (MRI) – has renewed interest in diagnosing adenomyosis with sufficient sensitivity, specificity and predictive value prior to any treatment. Furthermore, the direct visualization of the uterine cavity offered by hysteroscopy, which will be described in detail in this chapter, also broadens the possibilities of reliably diagnosing the entity in the office.

## DIAGNOSTIC HYSTEROSCOPY

Since modern diagnostic hysteroscopy is a procedure performed in the office, it is a technique that can be offered as a first-line diagnostic tool for evaluation of uterine abnormalities in patients with abnormal uterine bleeding (AUB) and/or infertility. Diagnostic hysteroscopy is performed by the gynaecologist at the same time as the physical exam and the TVS, and has the major advantage of permitting direct visualization of the pathology and selective exploration and treatment. While for AUB patients hysteroscopy offers an efficient organ-preserving technique, for infertile patients hysteroscopy offers the possibility of guaranteeing the normal structural

conditions for embryo implantation and placentation. Since the number of patients with infertility is constantly growing and the mean age of infertile couples is increasing, the probability of finding intrauterine pathologies is also increasing.

### The office approach for diagnostic hysteroscopy

The most important challenge for performing diagnostic hysteroscopy in the office is to be able to carry out the procedure with an acceptable patient compliance. This should not be underestimated since many patients still prefer the inpatient approach, believing that it will be pain-free.<sup>4</sup> Several alternatives have been proposed for pain reduction during conventional office diagnostic hysteroscopy, but the results are inconclusive.<sup>5–10</sup> The scientific evidence gathered over recent years and the major technical improvements in the manufacture of high-quality small-bored scopes (mini-hysteroscopes) have answered the question of how diagnostic hysteroscopy can be implemented successfully in an office environment (Table 1).<sup>11–17</sup>

The correct instrument selection, the atraumatic insertion technique, and the use of watery distension medium are essential for successful office hysteroscopy. It is very interesting to note that miniaturization of the instruments effectively counteracts the difficulties determined by both the operator and the patient, allowing the performance of office hysteroscopy even by less experienced gynaecologists and in the vast majority of patients<sup>13</sup>. The use of mini-hysteroscopes and saline distension medium still allows approach to the uterus either with the classic technique, in which a speculum is used to visualize the portio and the external cervical os, or with the vaginoscopic approach (i.e. vagino-cervico-hysteroscopy), which we advocate. Because a speculum impairs the liberal scope movement, frequently leading to the necessity of using a tenaculum, we have adapted the vagino-cervico-hysteroscopy technique since the early 1990s.

The procedure begins with a physical exam and a TVS to evaluate uterus characteristics. A vaginal disinfection with a non-irritating watery disinfection solution is performed without placing a speculum. The tip of the mini-hysteroscope is positioned in the vaginal introit, the labia being slightly separated with the fingers. The vagina is

**Table 1.** How office diagnostic hysteroscopy should be performed.

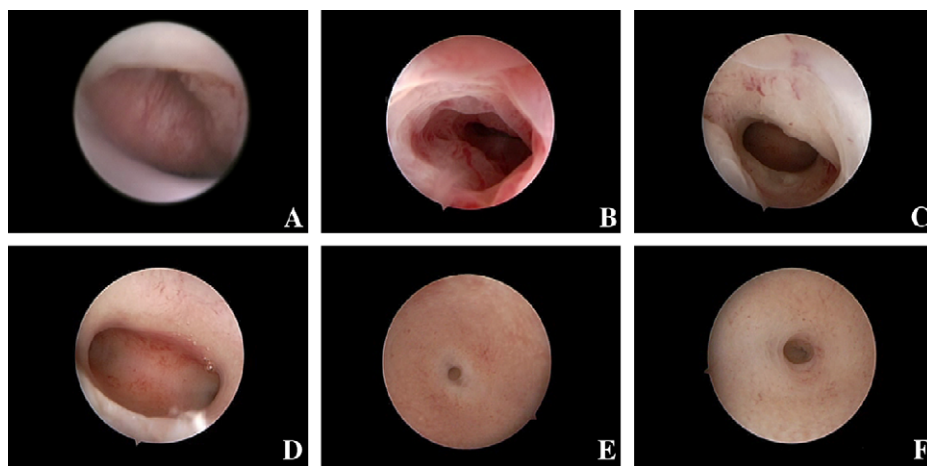
Hysteroscope:		
■ 30° rod lens optic	2.0 mm	2.8 mm
■ Diagnostic single flow sheath	2.9 mm	3.7 mm
Additional instruments and manoeuvres:		
■ Vaginal speculum	Not required	
■ Tenaculum	Not required	
■ Cervical dilatation	Not required	
Distension medium:	Low-viscosity fluids (e.g. saline) with pressure cuff at 80–100 mmHg	
Analgesia/anaesthesia:	Not required	

distended with the same medium used for the uterine cavity. In contrary to the distension of the uterus, the distension of the vagina does not provoke pain. The scope is driven to the posterior fornix to readily visualize the portio and slowly backwards to identify the external cervical os (Figure 1A). When this is visible, the scope is introduced into the cervical canal (Figure 1B), and after achieving its distension the scope is carefully moved forward to the internal cervical os (Figure 1C) and then to the uterine cavity with the least possible trauma. The uterine cavity is systematically explored by rotating the 30° fore-oblique scope in order to identify any anomaly in the uterine walls (Figure 1D) and/or the right (Figure 1E) and left (Figure 1F) tubal ostium. At this stage it is crucially important to avoid lateral movements as much as possible to reduce patient discomfort to a minimum. This approach requires a good knowledge of the physics and instrumentation as well as dexterity on the part of the operator (i.e. the correlation between what is seen on the screen and the actual position of the 30° fore-oblique scope). Immediately after the hysteroscopy, a second TVS is performed, taking advantage of the intracavitary fluid for a contrast image of the uterus.

### Indications for office diagnostic hysteroscopy



















The significant technical improvements in the field of hysteroscopy have allowed the performance of the procedure in the office and have therefore broadened the indications for diagnostic hysteroscopy (Table 2). Indeed, office diagnostic hysteroscopy can be indicated today in any situation in which a major or minor intrauterine anomaly is suspected or necessary to rule out, including asymptomatic patients, and for the purpose of endometrial surveillance during drug treatment.

As with conventional hysteroscopy, the main indication for office diagnostic hysteroscopy remains the evaluation of AUB, including the suspicion of endometrial polyps, submucous myomas and endometrial hyperplasia. Office diagnostic hysteroscopy is also indicated for the evaluation of cervical and uterine factors in patients with infertility, and especially in those who are scheduled to enter an IVF programme. Other indications include repetitive pregnancy wastage, suspected intrauterine



**Figure 1.** Hysteroscopy with the vaginoscopic approach. Visualization of the external cervical os (A), cervical canal (B), internal cervical os (C), uterine cavity overview (D), right tubal ostium (E), and left tubal ostium (F).

**Table 2.** Indications for office diagnostic hysteroscopy.

 	Abnormal uterine bleeding
 	Infertility
 	Abnormal findings at other diagnostic tests (e.g. ultrasound, hysterosalpingography, magnetic resonance imaging, blind biopsy)
 	Repetitive pregnancy wastage
 	Suspicion of uterine congenital anomalies
 	Suspicion of intrauterine adhesions
 	Misplaced foreign bodies (e.g. IUD)
 	Follow-up of medical (e.g. tamoxifen) or surgical treatment
 	Embryo evaluation (embryoscopy)

adhesions, congenital uterine anomalies, misplaced intrauterine foreign bodies (e.g. IUD), reported abnormal findings at ultrasound, hysterosalpingography, magnetic resonance image or blind biopsy, and follow-up of certain treatments with intrauterine repercussions (e.g. tamoxifene or intrauterine surgery). Furthermore, the already mentioned simplification of the technique and the consistent data published over recent years permits the proposal of office hysteroscopy as a first-line diagnostic tool for the investigation of AUB<sup>18,19</sup> and infertility.<sup>20–22</sup>

### Findings at diagnostic hysteroscopy

All hysteroscopic findings are recorded in a standardized pre-design form. A complete visualization of cervical canal, uterine cavity and tubal ostia and absence of any anatomical alterations is required to categorize the examination as normal. It is considered abnormal when any major or minor abnormality, regardless of its clinical significance, is detected. If for any reason (i.e. patient tolerance, technical or anatomical problems) insufficient visualization is achieved, it is stated that the examination failed to achieve a diagnosis. Major abnormalities are arbitrarily defined as those that structurally change the normal hysteroscopic anatomy (e.g. cervical stenosis, submucous myoma, polyps, congenital malformations, adhesions, necrotic tissue, tubal os stenosis). Minor abnormalities or subtle lesions indicate changes of the appearance without deformation of the normal anatomy, where the pathological significance is not always proven but where the hysteroscopic picture is different from the normal situation. These subtle or incipient lesions are described according to their hysteroscopic appearance and not to their supposed clinical significance (e.g. diffuse polyposis, hypervascularization, strawberry pattern, moderate/marked localized/generalized mucosal elevation, endometrial defect).

In a recently published prospective randomized trial we found that in the total population ( $n = 480$ ) the findings were normal in 55% of the cases and abnormal in 41% of the cases, while in 4% of the cases no diagnosis could be obtained.<sup>13</sup> Interestingly,

normal and abnormal findings were not equally distributed in patients with AUB or infertility. Indeed, in the AUB population ( $n = 230$ ) the findings were normal in 46% of the cases and abnormal in 51% of the cases, while no diagnosis could be obtained in 3% of the cases. In the infertility population ( $n = 219$ ), however, the findings were normal in up to 67% of the cases and abnormal in only 29% of the cases, and no diagnosis could be obtained in 4% of the cases. Furthermore, the specific findings were significantly different in both groups of patients (Figure 2; unpublished data). Specific suspicion for adenomyosis lesion was reported only in two cases in the AUB group (0.8%) and in no cases in the infertility group. Changes in the vascular architecture (e.g. strawberry pattern or hypervascularization) were diagnosed in 13 cases (5.6%) in the AUB group and in 13 cases (5.9%) in the infertility group. Those findings can be found with endometritis, adenomyosis, non-cyclic oestrogen environment or as a local reaction to a foreign body (Figure 3).

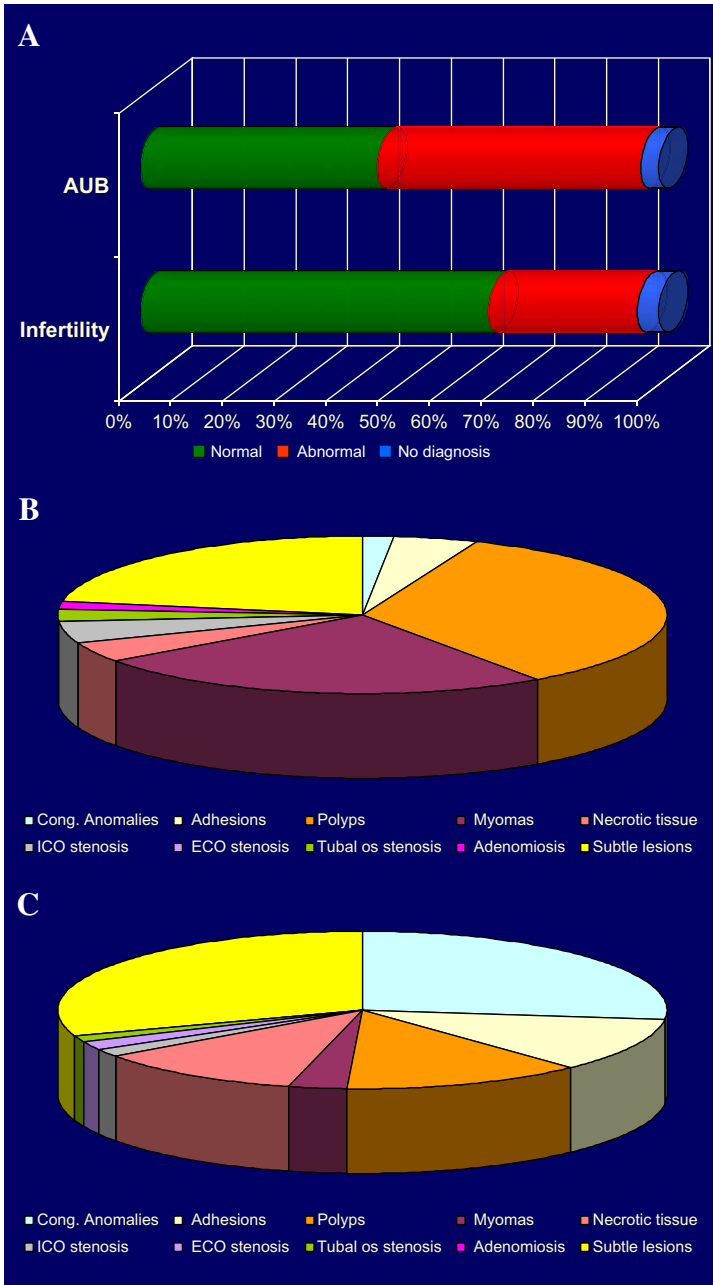
## HYSTEROSCOPY AND ADENOMYOSIS

Although hysteroscopy is unable to offer a pathognomonic sign for adenomyosis, some investigators have described the hysteroscopic uterine appearance of patients with adenomyosis.<sup>23–25</sup> There is some evidence that findings such as irregular endometrium with endometrial defects, hypervascularization, strawberry pattern or cystic haemorrhagic lesions are possibly associated with adenomyosis.

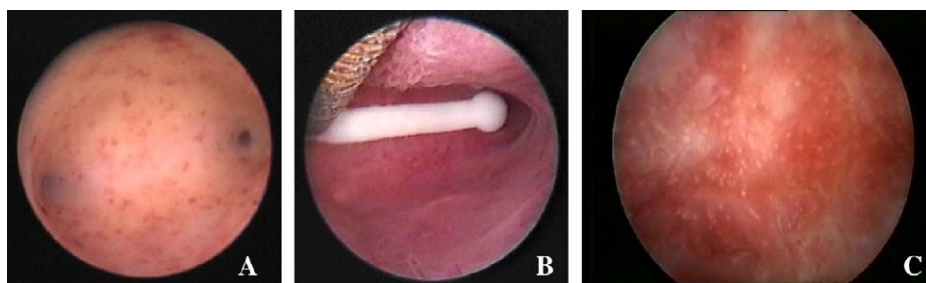
Similarly to hysterosalpingography, which occasionally reveals sac-like mucosal defects or multiple spiculations invading from the endometrial cavity into the myometrium,<sup>26</sup> during hysteroscopy small openings at the endometrial surface can be seen (Figure 4).

The available data on the hysteroscopic appearance of adenomyosis demonstrate an irregular endometrial vascular distribution in more than half of the patients. By morphological analysis of the endometrium, Ota and Tanaka<sup>25</sup> demonstrated that the mean surface area, total surface area, and total number of capillaries increased in the adenomyosis group both in the proliferative and secretory phases. In particular, the total surface of capillaries per  $\text{mm}^2$  rose markedly by 11.6 times compared to that of the control group in the proliferative phase. These findings strongly support the suggestion that the endometrium is functionally abnormal in patients with adenomyosis.

Puttemans et al<sup>27</sup> recently described a small, oval-shaped and translucent area on TVS (not surrounded by an echogenic border and 4 mm in diameter) in the fundus of the uterus in a 23-year-old patient with primary infertility of 20 months. This image persisted throughout her cycle. The patient was scheduled for an endoscopic infertility investigation, and diagnostic hysteroscopy revealed a dark blue cystic lesion on the anterior wall near the fundus (Figure 5). The dark blue colour originated from fluid blood in the centre of the lesion, whereas a biopsy of the bed of the lesion confirmed the diagnosis of adenomyosis. Only by reducing the intracavitary pressure can the superficial vascularization be inspected correctly. The endometrial biopsy showed a late proliferative endometrium without signs of endometritis. The transvaginal endoscopy and the tubal patency test were perfectly normal, without evidence of endometriosis. Six weeks after surgery an MRI of the pelvis confirmed the presence of a normal uterine junctional zone thickness without evidence of other focal areas of adenomyosis. One month later the patient became pregnant (spontaneous normal ongoing intrauterine singleton pregnancy).

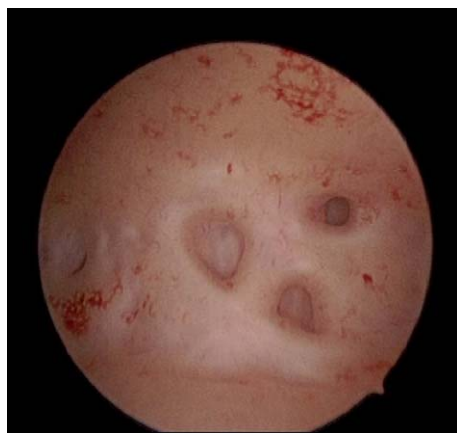

**Figure 2.** Hysteroscopy findings in patients with abnormal uterine bleeding (AUB) or infertility. (A) Distribution of normal and abnormal findings. (B) Abnormal findings in AUB patients. (C) Abnormal findings in infertility patients.



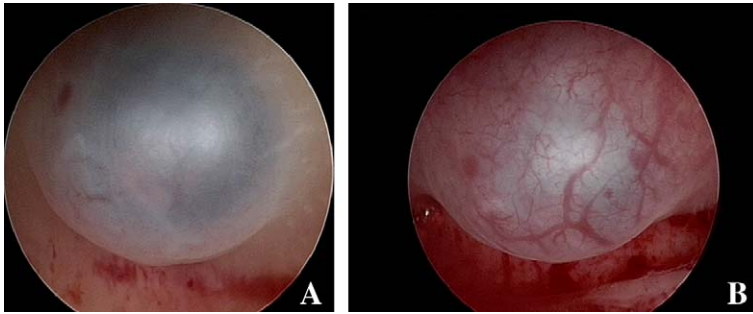
**Figure 3.** Hysteroscopic image of subtle lesions. (A) Normal uterine cavity with atrophic endometrium. (B) Endometrial hypervascularization giving reddish aspect due to intrauterine device. (C) Strawberry-like pattern.

In addition to the direct visualization of the uterine cavity, the hysteroscopic approach offers the possibility of obtaining histological specimens under visual control, allowing more accurate information to be obtained and correlations between images and histopathology to be made. Indeed, during hysteroscopy directed biopsies of the endometrium and underlying myometrium can be obtained either with the punch mechanical technique or with electrical loop resection. The visual control before, during and after loop resection may also demonstrate signs suggestive for adenomyosis. McCausland et al first described the technique of myometrial biopsy through the hysteroscope with loop resection,<sup>28</sup> and reported a prevalence of adenomyosis of 66% in AUB patients, demonstrating a positive correlation between the depth of the lesion and the severity of the menorrhagia. In a comparative study, Darwish et al demonstrated the superiority of loop resection over punch biopsy, reporting only 24% of adenomyosis in AUB patients.<sup>29</sup> The lower prevalence of adenomyosis in the later study could be explained by different histopathological criteria used for the diagnosis of adenomyosis. These and other studies demonstrated that hysteroscopy is suitable for diagnosing this entity, which must be suspected when the following signs are found.<sup>23</sup>



**Figure 4.** Hysteroscopy image of adenomyosis. During hysteroscopy small openings at the endometrial surface can be seen.





**Figure 5.** Hysteroscopy image of adenomyosis. (A) Cystic lesion with a dark blue colour originated from fluid blood in the lesion. (B) In the same lesions the superficial vascularization is seen by reducing the intra-cavitary pressure.

- irregular endometrium with superficial openings;
- irregular subendometrial myometrium (e.g. whorled, fibrotic, etc);
- absence of typical myometrial architecture during endometrial/myometrial loop resection; and
- intramural endometriomas.

## CONCLUSIONS

Although adenomyosis has traditionally been diagnosed by the pathologist in hysterectomy specimens, modern medicine demands an earlier diagnosis. The availability of high-quality non-invasive techniques such as TVS and MRI certainly helps in the pre-surgical diagnosis of adenomyosis, permitting programming and individualization of effective treatment to counteract not only AUB but also infertility. In this context, the direct visualization of the uterine cavity offered by hysteroscopy, which today can be performed in the office as a systematic and routine first-line procedure in patients with AUB and/or infertility, broadens the possibilities of detecting major or subtle changes in the endometrium that can be associated with adenomyosis.

Hysteroscopy cannot diagnose or exclude adenomyosis because its field of observation is limited to the endometrial surface. However, the minimal changes such as hypervascularization, strawberry pattern, cystic localized lesions or endometrial defects with an irregular endometrial lining are suggestive for myometrial pathology. Since it is well known that, in contrast to subserosal myomas, submucosal myomas negatively affect implantation rates after IVF, while the role of intramural myomas is controversial,<sup>30–38</sup> the pending question is whether myometrial pathology (e.g. adenomyosis) without any influence on the uterine cavity or on the endometrial surface has any clinical significance.

In this view the hysteroscopic findings of both subtle and major lesions could be of major clinical importance. As an office procedure the combination of TVS, fluid hysteroscopy and contrast sonography is nowadays the most powerful screening tool for detecting endometrial and myometrial abnormalities in association with adenomyosis.

## SUMMARY

New developments have made office hysteroscopy together with transvaginal endoscopy the first-line procedure for the investigation of uterine pathology in patients with

AUB and infertility. Although hysteroscopy is limited to observation of the surface of the endometrium, and can neither diagnose nor exclude adenomyosis, the visual inspection of the endometrium in patients with adenomyosis can reveal significant findings. As an office procedure the combination of TVS and hysteroscopy is, however, a powerful tool for detecting abnormalities, such as endometrial lesions or abnormal vascularization associated with adenomyosis.

## REFERENCES

- \*1. Uduwela AS, Perera MA, Aiqing L et al. Endometrial-myometrial interface: relationship to adenomyosis and changes in pregnancy. *Obstet Gynecol Surv* 2000; **55**: 390–400.
- \*2. Bird CC, McElin TV & Manalo-Estrella P. The elusive adenomyosis of the uterus—revisited. *Am J Obstet Gynecol* 1972; **112**: 583–593.
- \*3. Vercellini P, Trespidi L, Panazza S et al. Laparoscopic uterine biopsy for diagnosing diffuse adenomyosis. *J Reprod Med* 1996; **41**: 220–224.
4. Kremer C, Duffy S & Moroney M. Patient satisfaction with outpatient hysteroscopy versus day case hysteroscopy: randomised controlled trial. *BMJ* 2000; **320**: 279–282.
5. Davies A, Richardson RE, O'Connor H et al. Lignocaine aerosol spray in outpatient hysteroscopy: a randomized double-blind placebo-controlled trial. *Fertil Steril* 1997; **67**: 1019–1023.
6. Nagele F, Lockwood G & Magos AL. Randomised placebo controlled trial of mefenamic acid for pre-medication at outpatient hysteroscopy: a pilot study. *Br J Obstet Gynaecol* 1997; **104**: 842–844.
7. Wieser F, Kurz C, Wenzl R et al. Atraumatic cervical passage at outpatient hysteroscopy. *Fertil Steril* 1998; **69**: 549–551.
8. Wong AY, Wong K & Tang LC. Stepwise pain score analysis of the effect of local lignocaine on outpatient hysteroscopy: a randomized, double-blind, placebo-controlled trial. *Fertil Steril* 2000; **73**: 1234–1237.
9. De Angelis C, Perrone G, Santoro G et al. Suppression of pelvic pain during hysteroscopy with a transcatheter electrical nerve stimulation device. *Fertil Steril* 2003; **79**: 1422–1427.
10. Yang J & Vollenhoven B. Pain control in outpatient hysteroscopy. *Obstet Gynecol Surv* 2002; **57**: 693–702.
11. Nagele F, Bournas N, O'Connor H et al. Comparison of carbon dioxide and normal saline for uterine distension in outpatient hysteroscopy. *Fertil Steril* 1996; **65**: 305–309.
12. Shankar M, Davidson A, Taub N et al. Randomised comparison of distension media for outpatient hysteroscopy. *BJOG* 2004; **111**: 57–62.
- \*13. Campo R, Molinas CR, Rombauts L et al. Prospective multicentre randomized controlled trial to evaluate factors influencing the success rate of office diagnostic hysteroscopy. *Hum Reprod* 2005; **20**: 258–263.
14. Campo R, Van Belle Y, Rombauts L et al. Office mini-hysteroscopy. *Hum Reprod Update* 1999; **5**: 73–81.
15. Cicinelli E, Schonauer LM, Barba B et al. Tolerability and cardiovascular complications of outpatient diagnostic minihysteroscopy compared with conventional hysteroscopy. *J Am Assoc Gynecol Laparosc* 2003; **10**: 399–402.
16. Cicinelli E, Parisi C, Galantino P et al. Reliability, feasibility, and safety of minihysteroscopy with a vaginoscopic approach: experience with 6,000 cases. *Fertil Steril* 2003; **80**: 199–202.
17. De Angelis C, Santoro G, Re ME et al. Office hysteroscopy and compliance: mini-hysteroscopy versus traditional hysteroscopy in a randomized trial. *Hum Reprod* 2003; **18**: 2441–2445.
18. Loverro G, Bettocchi S, Cormio G et al. Transvaginal sonography and hysteroscopy in postmenopausal uterine bleeding. *Maturitas* 1999; **33**: 139–144.
19. Cooper JM & Brady RM. Hysteroscopy in the management of abnormal uterine bleeding. *Obstet Gynecol Clin North Am* 1999; **26**: 217–236.
20. Brosens I, Campo R, Puttemans P et al. One-stop endoscopy-based infertility clinic. *Curr Opin Obstet Gynecol* 2002; **14**: 397–400.
21. Campo R, Gordts S & Brosens I. Minimally invasive exploration of the female reproductive tract in infertility. *Reprod Biomed Online* 2002; **4**(supplement 3): 40–45.

22. Gordts S, Campo R, Puttemans P et al. Investigation of the infertile couple: a one-stop outpatient endoscopy-based approach. *Hum Reprod* 2002; **17**: 1684–1687.
23. Keckstein J. Hysteroscopy and adenomyosis. *Contrib Gynecol Obstet* 2000; **20**: 41–50.
- \*24. McCausland AM. Adenomyosis must be considered in patients with menorrhagia and a normal-appearing cavity on hysteroscopy or ultrasonography. *Am J Obstet Gynecol* 1995; **173**: 675.
- \*25. Ota H & Tanaka T. Stromal vascularization in the endometrium during adenomyosis. *Microsc Res Tech* 2003; **60**: 445–449.
26. Marshak RH & Eliasoph J. The roentgen findings in adenomyosis. *Radiology* 1955; **64**: 846–851.
- \*27. Puttemans P, Molinas R, Gordts S et al. Hysteroscopic images of an isolated lesion of unknown origin in a young infertile patient. *J Minim Invasive Gynecol* 2005; **12**: 104–105.
- \*28. McCausland AM. Hysteroscopic myometrial biopsy: its use in diagnosing adenomyosis and its clinical application. *Am J Obstet Gynecol* 1992; **166**: 1619–1626.
- \*29. Darwish AM, Makhlof AM, Yousof AA et al. Hysteroscopic myometrial biopsy in unexplained abnormal uterine bleeding. *Eur J Obstet Gynecol Reprod Biol* 1999; **86**: 139–143.
30. Eldar-Geva T, Meagher S, Healy DL et al. Effect of intramural, subserosal, and submucosal uterine fibroids on the outcome of assisted reproductive technology treatment. *Fertil Steril* 1998; **70**: 687–691.
31. Healy DL. Impact of uterine fibroids on ART outcome. *Environ Health Perspect* 2000; **108**(supplement 5): 845–847.
32. Stovall DW, Parrish SB, Van Voorhis BJ et al. Uterine leiomyomas reduce the efficacy of assisted reproduction cycles: results of a matched follow-up study. *Hum Reprod* 1998; **13**: 192–197.
33. Hart R, Khalaf Y, Yeong CT et al. A prospective controlled study of the effect of intramural uterine fibroids on the outcome of assisted conception. *Hum Reprod* 2001; **16**: 2411–2417.
34. Ramzy AM, Sattar M, Amin Y et al. Uterine myomata and outcome of assisted reproduction. *Hum Reprod* 1998; **13**: 198–202.
35. Surrey ES, Minjarez DA, Stevens JM et al. Effect of myomectomy on the outcome of assisted reproductive technologies. *Fertil Steril* 2005; **83**: 1473–1479.
36. Surrey ES. Impact of intramural leiomyomata on in-vitro fertilization-embryo transfer cycle outcome. *Curr Opin Obstet Gynecol* 2003; **15**: 239–242.
37. Surrey ES, Lietz AK & Schoolcraft WB. Impact of intramural leiomyomata in patients with a normal endometrial cavity on in vitro fertilization-embryo transfer cycle outcome. *Fertil Steril* 2001; **75**: 405–410.
38. Oliveira FG, Abdelmassih VG, Diamond MP et al. Impact of subserosal and intramural uterine fibroids that do not distort the endometrial cavity on the outcome of in vitro fertilization-intracytoplasmic sperm injection. *Fertil Steril* 2004; **81**: 582–587.